



PATIENT

Walter Chandler

SPECIES

Canine

BREED

Chihuahua

SEX

Male Neutered

AGE

10 years

WEIGHT

20.1lbs

INTERPRETED BY

Maggie Machen Lamy,
DVM, DACVIM
(Cardiology)

IMAGING PERFORMED BY

Loetitia Saint-Jacques,
LVT

HOSPITAL NAME

North Fork VC

REFERRING VET

Dr. Marss

INVOICE

47490

DATE

4/8/26

PRESENTING CLINICAL SIGNS

History: Recheck echo. Grade 5/6 heart murmur. Asymptomatic. On Enalapril 5mg BID, Pimobendan 2.5mg BID, Ursodiol 125mg SID. BP (3/22025): 140mmHg.

-Abnormal PE/Chem/CBC/UA Results: Lab work 3/10/26: ALT 148, ALL 618, renal values WNL, USG 1.022, UPC 0.3.

-Pertinent previous echo findings (9/2025 MML/LSJ): CVD B2. Mild MR, mild LAE, trace TR. Improved from previous. LA: 2.2. LVOT obstruction; AV max: up to 4.0m/s. No LVH.

ECHOCARDIOGRAM FINDINGS

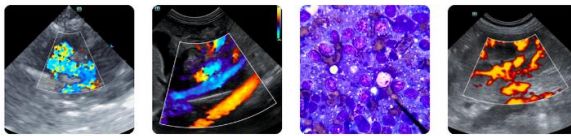
2D, m-mode, color flow and doppler imaging is available. Mild diffuse thickening of mitral valve leaflets with mild prolapse into the left atrial lumen. Mild eccentric mitral regurgitation with mild left atrial dilation. Normal MR velocity. Normal LV diameter with adequate myocardial function. The tricuspid valve appears normal with trace tricuspid regurgitation. Normal velocity. Normal right atrial and ventricular diameter and morphology indicating no overt evidence of pulmonary arterial hypertension. The pulmonic and aortic valves are normal in morphology and mobility. Mildly elevated pulmonic outflow velocities with a dynamic profile. The aortic outflow velocity is quite variable, depending on HR with an increased velocity overall. Mild aortic and no pulmonic insufficiency. No pericardial or pleural effusion noted. No obvious cardiac masses.

CARDIAC CHART

CANINE CARDIAC PARAMETERS	MR VMAX (m/s)	TR VMAX (m/s)	LA/AO (Boon method)	LA/AO (Heart Base; Swe)	FS (%)	EF (%)	EPSS (cm)
NORMAL PARAMETER	4.5-5.5	<2.7	1.3	<1.6	28-40	40-100	<0.6
PATIENT	5.0	2.6	NM	1.5	47	81	NM
CANINE CARDIAC PARAMETERS	HR (BPM)	AV VMAX (m/s)	PV MAX (m/s)	BODY WEIGHT (kg)	LA 2D short axis Base view (cm)	LVIDd Avg; 2D and m-mode short axis (cm)	LVIDs Avg; 2D and m-mode short axis (cm)
NORMAL PARAMETER	50-100	0.7-1.7	0.7-1.6	BELOW	BELOW	BELOW	BELOW
PATIENT	104	>4.0	2.5	9.1	2.2	2.3	1.2
*Normal chamber parameters expressed as a mean value (SD)				3	1.27 (5.3)	2.46 (2.46)	1.36 (5.5)
BODY WEIGHT DEPENDENT PARAMETERS				5	1.40 (4.5)	2.74 (5.2)	1.60 (4.7)
*Note: All measurements based upon multi-modal images and methods. An average value is reported.				10	1.50 (3.8)	3.27 (3.5)	2.06 (3.1)
				15	1.83 (2.0)	3.71 (2.4)	2.43 (2.1)
				20	2.02 (1.9)	4.14 (2.2)	2.80 (2.0)
				25	2.18 (2.4)	4.48 (2.9)	3.10 (2.5)
				30	2.33 (3.3)	4.83 (3.9)	3.39 (3.4)
				35	2.48 (4.3)	5.17 (5.0)	3.69 (4.5)
				40	2.62 (5.2)	5.48 (6.1)	3.96 (5.4)
				50	2.88 (7.1)	6.07 (8.3)	4.46 (7.4)

INTERPRETATION OF THE FINDINGS & FURTHER RECOMMENDATIONS

Persistently stable findings. The LVOT obstruction remains apparent, yet no significant LV hypertrophy has developed suggesting primarily a stressed-related phenomenon. The pulmonic



PATIENT

Walter Chandler

SPECIES

Canine

BREED

Chihuahua

SEX

Male Neutered

AGE

10 years

WEIGHT

20.1lbs

INTERPRETED BY

Maggie Machen Lamy,
DVM, DACVIM
(Cardiology)

**IMAGING
PERFORMED BY**

Loetitia Saint-Jacques,
LVT

HOSPITAL NAME

North Fork VC

REFERRING VET

Dr. Marss

INVOICE

47490

DATE

4/8/26

outflow is also slightly increased, which also appears benign. Mild MR is unchanged and the overall dimensions and function are similar to previous.

Given these findings, reasonable to continue Pimobendan and Enalapril. Continued assessment of progression in the future will help predict long term prognosis, which is highly variable at this stage (B1/B2). Omega fatty acid supplementation and mild salt restriction may be of some long-term benefit. Monitor for development of a cough, labored breathing, exercise intolerance or collapse episodes.

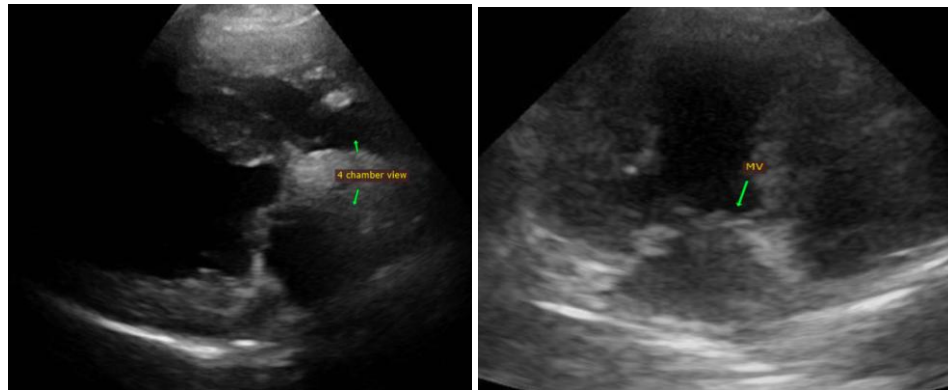
Anesthetic risk is considered mild if needed. Cardiac protective drug choices (opioid/benzodiazepine premedication, propofol or alfaxalone induction, isoflurane gas) are recommended. Pre-oxygenate for 5-10 minutes prior to induction. Monitor for arrhythmias, hypotension, and hypoxia both intra and post-operatively and intervene as necessary. Mild IV fluid restriction is recommended to avoid fluid overload. Avoid heart rate stimulating drugs such as atropine unless clinically indicated.

PLAN:

Continue ACE-I 0.5mg/kg PO q12h. Continue Pimobendan 0.3mg/kg PO q12h.

Recommend conservative monitoring with a recheck echocardiogram in 6-12 months, sooner if any development of clinical signs.

IMAGES



The information and recommendations provided are based on the images presented by the referring veterinarian. No evaluation can be communicated regarding pathology that was not visible in the image/video clips provided.

Thank you for this referral. This report was generated using transcription software, and minor dictation errors may be present. If the clinical or image interpretation does not parallel your findings or if I can be of any further assistance, please contact me.

Maggie Machen Lamy, DVM
Diplomate of the American College of Veterinary Internal Medicine (Cardiology)
info@sonopath.com